

# 2025 EBO Comprehensive Exam (Online)

Tristan Bourcier, Anna Maino,  
Brendan Strong & Lisa Flanagan



## Where, When & How?

### **You will take this exam online on May 16th:**

- MCQ in the morning (10:00 CEST– 120 mins)
- Clinical Cases in the afternoon (14:00 CEST– 80 mins)

### **You will need:**

- Your ID (Driver's license, passport, etc)
- Laptop (Windows or MacBook) connected to high-speed, stable internet
- Use Google Chrome browser
- Webcam, microphone must be activated, have a charger cable with you
- You will be remotely proctored by ProctorExam
  - Example: <https://proctorexam.com/test-taker-support/>

# Where, When & How?

2 platforms will be used:



ProctorExam is an online service that will monitor you taking the exam



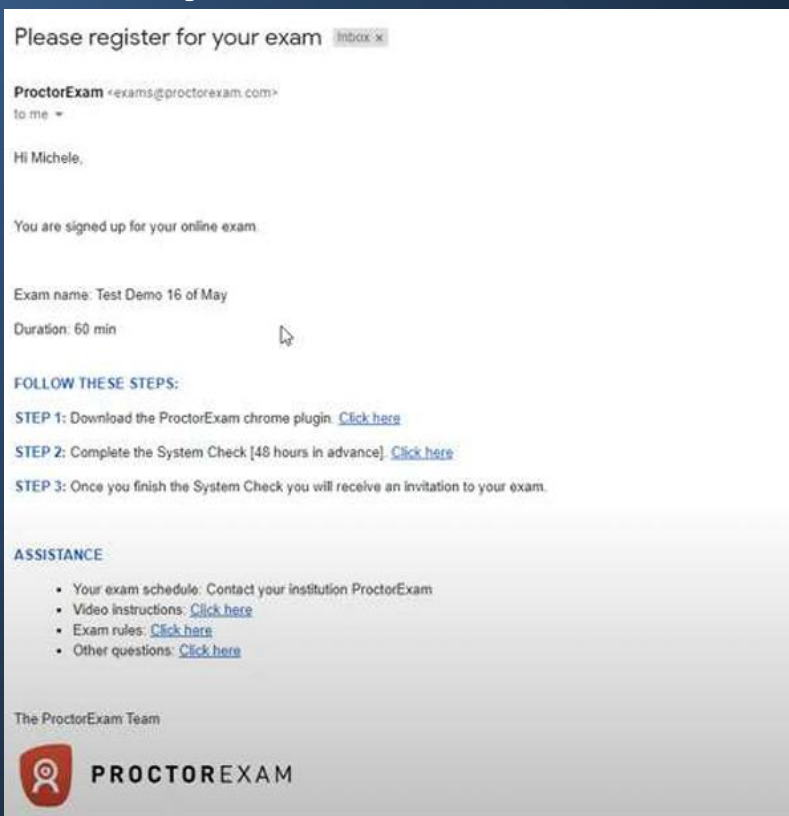
Speedwell eSystem is where you answer the exam questions

# Technical Preparation for May exam

## 10 days to 1 week before exam:

- Connection test to Speedwell eSystem and trial exam
  - Login and password sent for test
  - Familiarise yourself with technical interface
- System test with ProctorExam to check your set up
  - **Email will come from ProctorExam**
  - Up to 48 hours before
- **On exam day: Log into ProctorExam system**

# ProctorExam System Check




- System check **1 week to 10 days** before the exam
  - **Email will come from ProctorExam**
  - You must perform system check on the computer and in the place where you will use to take the exam
  - This will identify any issues you may need to fix before the exam
  - Note: They mention a smartphone app – **we do not use this**
  - **2 emails**: one for each exam (MCQs and Clinical Cases)
- You will only receive your exam link once you complete the system check!**

## How?

- **Alone** in the room, **for the full duration** of the exam (you cannot leave and return multiple times)
- One pencil and empty paper allowed
- One bottle of water and one snack allowed
- Headphones, headsets, airpods and earphones are **NOT** permitted
- You may **NOT** use a second screen for the exam
- Restroom is allowed **ONCE** for five minutes but the exam countdown will continue. **You must let the remote invigilator know if you are going to the restroom**
- Technical invigilation provided for IT questions (through chat box)
- Clinical invigilation not provided: no questions concerning exam content during exam

# Rules for the exams

## ALLOWED

- Blank paper
- Pencil
- Snack
- Bottle of water
- Restroom break for one time - the exam countdown continues 
- Technical questions (IT)

## NOT ALLOWED

- Phones
- Headphones, headsets
- Smartwatches
- Earphones, airpods
- Books, dictionaries, Google Translate
- Questions about exam content

## MCQ exam

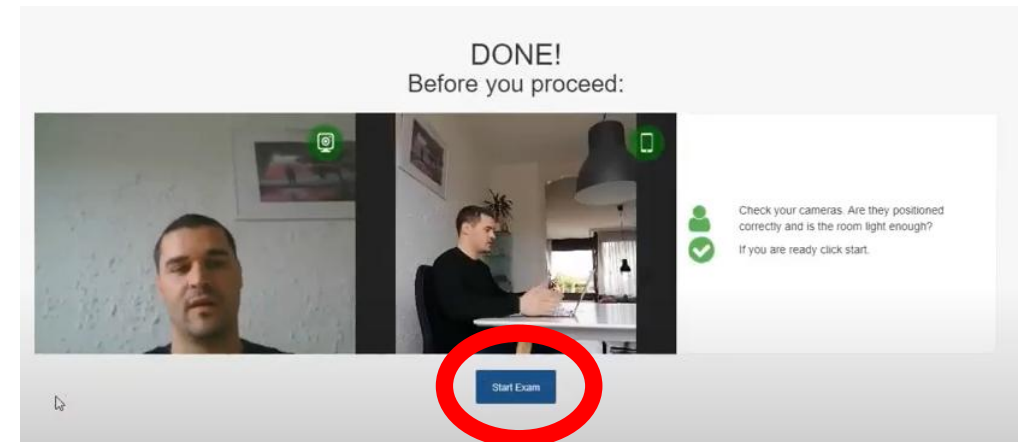
- 10:00 CEST
- 60 questions covering the complete program: basic science, medical or surgical topics
- 30 Multiple T/F Questions | 30 Single Best Answer Questions
- **NO** negative marking
  - Correct = 1 point
  - Incorrect = 0
- $\langle \text{Average score} - 1 \text{ Standard Deviation} \rangle = 6$  (Pass mark)
  - Score will be rescaled from 1 – 10
  - Must achieve 6 or higher in MCQ to pass exam
- 40% of overall score

**Invigilation by remote proctor (ProctorExam)**



# MCQ exam

- Connect via link from ProctorExam in Google Chrome (**Check it is the correct link for PART I**)
- Meet the proctor (via chatbox) and do 3 checks:
  - System
  - ID
  - Roomscan



- You will be automatically logged into the Speedwell eSystem from there
- Exam opens in new tab –keep ProctorExam Tab open

30 Multiple  
True / False  
Questions  
(This is an  
example)

☰ Questions 1 to 5 of 60 Time Remaining: 00:28:32

EBO Test Exam

Options:

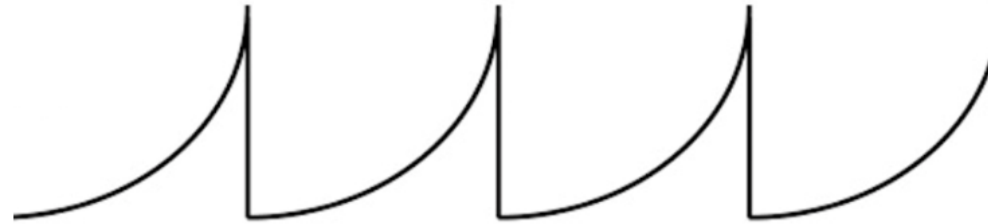- A. TRUE
- B. FALSE

A 5-year old boy, tall for his age with long thin fingers and hyperextensible finger joints, presents with bilaterally subluxated lenses, one down and in and the other up and out. Both parents are normal and there is no family history:

1. The most likely diagnosis is Weill-Marchesani syndrome
2. An electroretinogram is indicated
3. Visual acuity is best helped by aphakic or phakic spectacle correction based on retinoscopy and subjective refinement
4. In the differential diagnosis an autosomal recessive disease such as homocystinuria should not be considered
5. An echocardiogram should be performed

30 SBA  
questions  
(This is an  
example)

A 3 year old girl has been referred to the paediatric ophthalmology clinic because of unusual eye movements. The eye movements were noticed by the kindergarden staff. Parents were not aware of any problem. The child is fit and well and there is no family history of eye problems. Visual acuity is 0.9 (9/10 decimals, 0.100 LogMAR) in each eye. Anterior and posterior segment examination is normal. On examination, there is horizontal nystagmus in all positions of gaze. The frequency and amplitude of nystagmus increases significantly when the child fixes on a distance target. Eye-tracker testing shows this waveform pattern:



**What is the most likely diagnosis?**

- Vestibular nystagmus
- Pendular nystagmus
- Manifest latent nystagmus
- Congenital idiopathic nystagmus

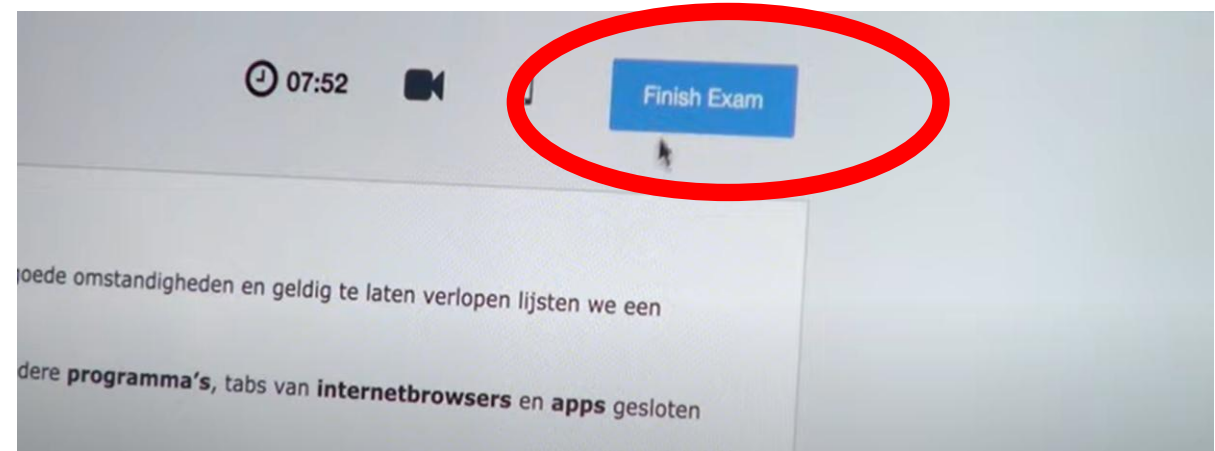
|    |                                      |       |        |
|----|--------------------------------------|-------|--------|
| 59 | May require penetrating keratoplasty | TRUE  | Review |
| 60 | Starts in early childhood            | FALSE | Review |

If you are happy with your answers, press the Finished button to complete the exam. You will not be able to change your answers after this.



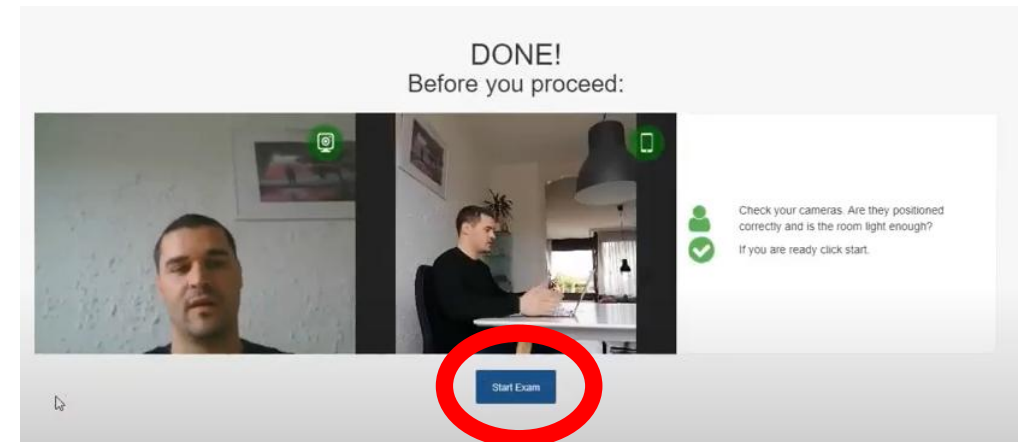
When you complete the MCQ section...

**Close this tab, go back to ProctorExam tab and click “Finish Exam”**



# Clinical Cases exam

- Connect via link from ProctorExam in Google Chrome (**Check it is the correct link for PART II**)
- Repeat process from earlier (MCQ Exam)
- Meet the proctor (via chatbox) and do 3 checks:
  - System
  - ID
  - Roomscan



- You will be automatically logged into the Speedwell eSystem from there
- Exam opens in new tab –keep ProctorExam Tab open

# Clinical Cases

- 14:00 CEST
- 8 cases in 80 minutes
- Around 5 questions per case
- English language
- Standardized cases, questions and answers
- 60% overall score
- Score will be rescaled similar to MCQ Score

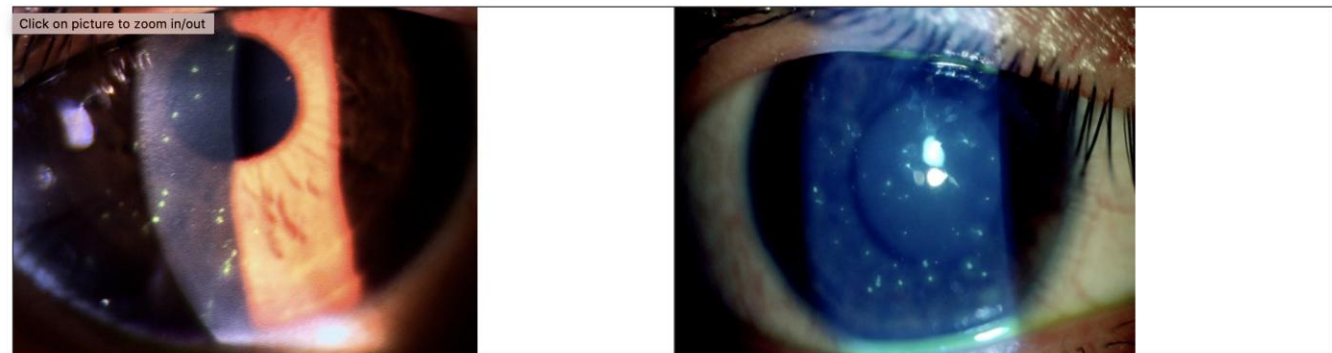
|                               |                            |
|-------------------------------|----------------------------|
| A1- Optics, Refraction, Neuro | A2- Pediatrics, Strabismus |
| B1- Cornea, External          | B2- Orbit, Adnexa          |
| C1- Glaucoma                  | C2- Cataract, Refractive   |
| D1- Retina                    | D2- Uveitis                |

☰ Question 1 of 29

Patient History:

- 27 year-old man
- Photophobia and foreign body sensation in both eyes for 2 days
- Vision has decreased "a bit"

For this case, over the next few screens you will be asked to identify important features, your diagnosis and treatment options.



**Identify one of the key features you see here (you will be asked to identify two more on the next two screens).**



**EXAMPLES** of the questions you will be asked

- Describe what you see in the image
- What disease would you suspect?
- What is the most important diagnostic test?
- What is the diagnosis?
- What is the treatment?

# Clinical Cases

# Scoring & Standard Setting

Outcome is a combination of:

- 40% MCQ (rescaled from 1 – 10)
- 60% Viva Voce (rescaled from 1 – 10)

Notes:

- **6 or higher is the pass mark** for each section
- You must achieve a **6 or higher in MCQ** to pass
- You must achieve a **6 or higher overall** to pass
- You may achieve **one** score less than 6 in viva voce, if your overall score is higher than 6

**Results released in 2 weeks (estimate)**